

A Novel Technique for Correcting Radial Length and Translation in Distal Radius Fractures

William L. Wang, MD* and Rick Tosti, MD†

Abstract: We describe a novel technique in correcting distal radius fractures deformed with significant shortening or coronal plane translation in both the acute or chronic setting. The technique involves using a modified push-pull device to assist the surgeon in correcting length and/or translation of the articular block without the use additional hardware outside of the volar plate.

Key Words: distal radius fracture technique, distal radius fracture length and translation correction, distal radius expander tool technique

(*Tech Hand Surg* 2018;22: 116–119)

Distal radius fractures are the most common upper extremity fracture, representing 16% of all fractures seen in the emergency department.^{1–3} The incidence is usually bimodal with the highest frequency observed in youths under the age of 18 and a secondary peak reported in adults over 50 years old.¹ Over the last 40 years, the prevalence of distal radius fractures has increased, particularly in the elderly and pediatric populations.⁴ Upper extremity surgeons commonly encounter both acute unstable fractures and deformed malunited fractures, which may lead to pain and dysfunction if normal anatomic parameters are not restored. In such cases, malunited fractures have the potential to cause complications such as posttraumatic arthrosis, distal radioulnar joint instability (DRUJ), carpal tunnel syndrome, ulnar-carpal abutment syndrome, and midcarpal instability.^{5–8}

Many surgical techniques have been described to aid the surgeon in restoring the patient's proper length, alignment, and rotation. We present a simple, novel surgical technique for correcting length and/or translation of the articular distal articular fragment in either acute or chronic distal radius fractures by using an expander tool originally designed for ankle fractures.

ANATOMY

The articular surface of the distal radius is biconcave and composed of hyaline cartilage. In the normal wrist, the radial height averages 11.6 mm, the radial inclination averages 23.6 degrees, and the volar tilt averages 11.2 degrees.⁹ The ulnar variance is usually neutral plus or negative 2 mm. In the normal wrist, the radius absorbs ~80% of the compressive load with the ulna absorbing the remaining 20% through the triangular

fibrocartilage complex (TFCC). Some deformity can be tolerated without significant loss of function.^{10,11} Generally, acceptable radiographic parameters include volar tilt <10-degree dorsal or 20-degree volar, articular step off <2 mm, radial height with <5 mm of shortening, and radial inclination >15 degrees. However, with a disproportionate loss of height, the ulnar variance becomes more positive which places increased load on the ulnar side of the wrist, causing pain and degeneration.

The stability of the DRUJ can also be affected by deformities of height, volar tilt, or displacement of the articular fragment. In addition to bony congruity, stabilization of the DRUJ also requires competent soft tissue constraints such as the dorsal and palmar radioulnar ligaments of the TFCC,¹² and the distal interosseous membrane (DIOM).^{13,14} In the sagittal plane, excessive dorsal or volar displacement of the articular segment may disrupt the distal radioulnar ligaments. In the coronal plane, excessive radial displacement of the articular segment with an ulnar translated shaft can cause incongruity in the DRUJ. This can occur with fractures that extend directly into the DRUJ or with extra-articular fractures that detension the DIOM, causing DRUJ laxity.^{8,15,16}

INDICATIONS AND CONTRAINDICATIONS

The indications for open reduction internal fixation of distal radius fractures are well known and most commonly include those for which fracture deformity is predicted to produce a functional deficit. Operative indications include unacceptable

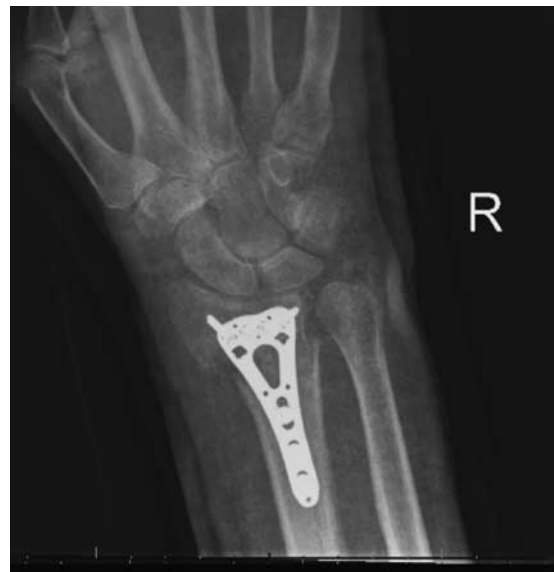

FIGURE 1. Fracture treated with volar plating with residual ulnar translation of the proximal shaft and radial translation of the articular segment. This patient was unsatisfied with the appearance of the wrist and had pain with forearm rotation.

From the *Department of Orthopaedic Surgery; and †Philadelphia Hand to Shoulder Center, Sidney Kimmel Medical College, Thomas Jefferson University, Philadelphia, PA.

Research for this manuscript was conducted at Thomas Jefferson University Hospital.

Conflicts of Interest and Source of Funding: The authors report no conflicts of interest and no source of funding.

Address correspondence and reprint requests to William L. Wang, MD, Department of Orthopaedic Surgery, Sidney Kimmel Medical College, Thomas Jefferson University, Philadelphia, PA 19107.

E-mail: wliuwang@gmail.com.

Copyright © 2018 Wolters Kluwer Health, Inc. All rights reserved.

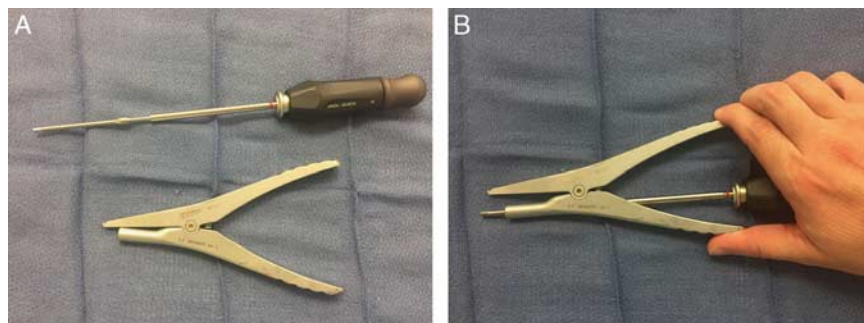


FIGURE 2. The screwdriver (A) is inserted into the slotted hole of the expander/compression tool (B). full color online

reduction, predicted or established instability, intra-articular displacement or comminution, open fracture, associated neurovascular or tendon injury, associated carpal bone fracture, bilateral injury or contralateral impairment, nonunion, and malunion. With specific regard to the technique described herein, the primary indication is a distal radius fracture that is deformed by shortening or coronal plane translation (Fig. 1). We have found this technique particularly useful in the setting of corrective procedures for malunions or nonunions during which soft tissue contractures hinder the reduction. Although not an absolute contraindication to using this technique, the surgeon should be cautious of iatrogenic fractures that could occur at the pivot screw in severely osteoporotic bone.

OPERATIVE TECHNIQUE

Anesthesia and Patient Positioning

Surgery is performed under general anesthesia or intravenous regional anesthesia with or without a tourniquet. The patient is placed in a supine position with operative forearm on an arm board with palm facing upward.

Surgical Technique

A volar approach is made to the distal radius and the fracture fragments are debrided and provisionally reduced with manipulation. A temporary Kirschner wire (K-wire) can be used to initially reduce the fracture. The volar plate is positioned proximal to the watershed line on the distal fragment and secured with temporary K-wires. Fluoroscopic images are then obtained to assess the position of the plate and trajectory of the screws. A long cortical screw is secured first in the distal row to compress the plate to the bone, which is then followed by subcortical locking screws. The cortical screw in the distal fragment is then replaced for an appropriately sized locking screw.

If the surgeon assesses the preliminary reduction and judges that more length or translation is required, then the expander technique can be used. The expander/compression tool was designed by Trimed (Santa Clarita, CA) originally as a compression device for transverse or short oblique distal fibula fractures. We have modified the use of the tool to include it as a reduction device for distal radius fractures and routinely store it with this set.

To use the expander as a device to gain length or correct translation, first a single cortical screw is placed distally in the oblong hole. We advise using a screw length 2 mm longer than the measured distance across the 2 cortices so that both cortices are engaged during the correction. We have found shorter screws, although more expeditious, increase the stress on the volar cortex and may cause it to fracture. The first cortical shaft screw should partly engage the far cortex and not be completely tightened so that the plate is able to glide or rotate in the oblong shaft hole. If a temporary K-wire was placed across the fracture site, it should be removed after the cortical screw is placed but before the correction with the expander tool.

The expander tool is assembled on the back table. The screwdriver is sized for the larger cortical shaft screws and inserted through the slotted handle (Fig. 2). Although the expander tool is specifically designed for Trimed, any screwdriver that is designed to be long and thin could theoretically fit through the slot. The screwdriver then engages the cortical screw in the shaft, and the hook end is placed into the next distal screw hole. The surgeon simply squeezes the handle to gain the desired amount of length, and then turns the screwdriver to fully engage the cortical shaft screw (Fig. 3). The surgeon additionally can adjust the translation of the articular block. While keeping the hook engaged, the surgeon squeezes the handle to create space and then rotates the hook segment toward the ulna. The distal segment will pivot around the single shaft screw to reduce the translated segment (Fig. 4). While

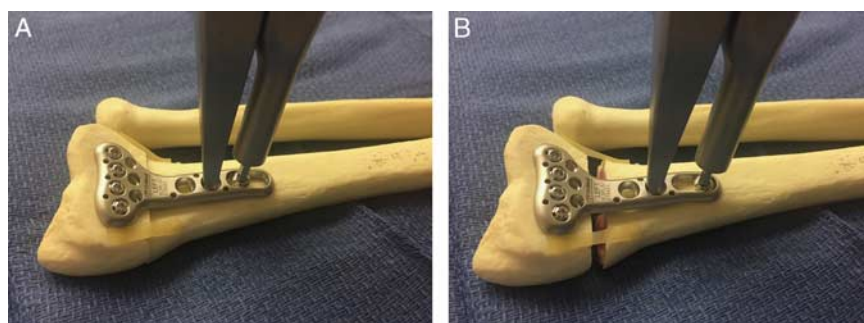


FIGURE 3. A shortened fracture (A) can be easily lengthened (B) by squeezing the device. full color online

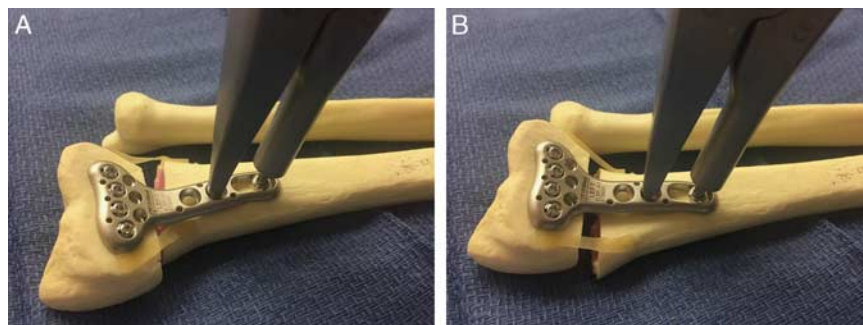


FIGURE 4. A translated articular block (A) can be corrected by rotating the distal tine ulnarly (B). [full color online](#)

holding the reduction, the cortical screw is then turned to fully engage the far cortex.

If the alignment is satisfactory, the remaining shaft holes are filled. Usually the first cortical shaft screw that was used a reduction screw would be replaced with another screw of a shorter length.

Postoperative Care and Rehabilitation

The patient is initially placed in a sterile dressing and postoperative volar wrist splint. At the first postoperative visit, the patient is transitioned to a removable splint and allowed to perform active range of motion at the wrist. Strengthening and progression to weight-bearing may progress as the fracture consolidates usually around 6 to 8 weeks.

COMPLICATIONS

The risk for iatrogenic fracture is increased in severely osteoporotic bone. The weight of the wrist is concentrated on 1 cortical screw as the expander distracts the fracture. We have found this risk less if a longer cortical screw is used that engages both cortices. Because of the ease at which the fracture gap is lengthened, the surgeon could also leave a significant cortical defect. In such cases, we would recommend either lessening the distraction or filling the void with bone graft.

DISCUSSION

Outcomes following operative fixation of distal radius fractures are optimized with proper restoration of the native anatomy.⁵ A shortened radius may lead to persistent ulnar wrist pain due to the increased compressive forces exerted on ulna through the TFCC or impingement into the ulnar-carpal bones.^{17,18} Regaining length in a shortened fracture can be challenging, especially in chronic injuries with soft tissue contractures. Nonetheless, this can still be achieved with several techniques. Probably the simplest method involves a tenotomy of the brachioradialis tendon and releasing the periosteal soft tissues with an extended flexor carpi radialis approach; however, excessive stripping may disrupt the osseous vascular supply could potentially lead to delays in fracture healing.¹⁹ Length can also be restored by placing a separate cortical screw proximal to the plate and using it as a backstop. With this method, a lamina spreader or an articulating tensioning device can be placed between the screw and plate to “push” the plate and articular block into distraction.¹⁷ Jupiter and Ring alternatively described using a small skeletal distractor (Synthes, Paoli, PA) for lengthening chronic nonunited distal radius fractures. In their series, 2 Schanz pins were placed on

either side of the fracture to gain length before fixation as a 1- or 2-stage procedure.^{20,21}

Radial translation of the articular fragment with respect to the proximal fragment is a commonly occurring deformity, but the clinical significance is still not well understood. A biomechanical study by Moritomo and Omori⁸ suggested that coronal plane translation slackens the DIOM and increases laxity at the DRUJ in the presence of a TFCC tear. Ross et al²² suggested that excessive translation might cause abutment between the proximal shaft and the ulna and instability at the DRUJ. However, a biomechanical study by Hepper et al²³ did not show significant decreases in forearm rotation in with increasing translation. Even if a functional deficit is not present, the patient may be displeased with the cosmetic appearance of the wrist if a translated distal radius is ignored by the surgeon.

Several methods exist to correct radial translation of the distal fragment. If using an external fixator, the shaft pins can be inserted and locked into the bar first, then the surgeon could pull the shaft radially before tightening the distal pins. If using a radial incision, a radial-sided plate could be placed to reduce the deformity. If using a volar incision, a lamina spreader or a Gelpi retractor can be placed into the interosseous space to translate the proximal fragment radially. Similarly, an army-navy retractor can be placed into the interosseous space and rotated 90 degrees.²⁴ Finally, the surgeon could use a pivot screw as described with the expander technique, but use a serrated bone clamp with one tine on the proximal ulnar cortex and one tine on the distal radial cortex. The clamp can be tightened and rotated to achieve a reduction before the screw is fully engaged.

We believe the expander tool has several advantages and warrants consideration as another tool in the surgeon’s armamentarium, particularly in the setting of malunion correction. The technique allows the surgeon to simultaneously correct length and translation. In addition, a surgeon does not require an assistant to pull traction or hold a retractor using this technique. Finally, a surgeon does not require additional hardware such as screws, Schanz pins, or radial column plates, all which would increase surgical time and risk of adverse events.

REFERENCES

1. Karl JW, Olson PR, Rosenwasser MP. The epidemiology of upper extremity fractures in the United States, 2009. *J Orthop Trauma.* 2015;29:e242–e244.
2. Chung KC, Spilson SV. The frequency and epidemiology of hand and forearm fractures in the United States. *J Hand Surg.* 2001;26:908–915.
3. Larsen CF, Lauritsen J. Epidemiology of acute wrist trauma. *Int J Epidemiol.* 1993;22:911–916.

4. Nellans KW, Kowalski E, Chung KC. The epidemiology of distal radius fractures. *Hand Clin.* 2012;28:113–125.
5. Jupiter JB, Fernandez DL. Complications following distal radial fracture. *J Bone Joint Surg.* 2001;83:1244–1265.
6. Adams BD. Effects of radial deformity on distal radioulnar joint mechanics. *J Hand Surg Am.* 1993;18:492–498.
7. Kihara H, Palmer AK, Werner FW, et al. The effect of dorsally angulated distal radius fractures on distal radioulnar joint congruency and forearm rotation. *J Hand Surg Am.* 1996;21:40–47.
8. Moritomo H, Omori S. Influence of ulnar translation of the radial shaft in distal radius fracture on distal radioulnar joint instability. *J Wrist Surg.* 2014;3:18–21.
9. Medoff RJ. Essential radiographic evaluation for distal radius fractures. *Hand Clin.* 2005;21:279–288.
10. Ilyas AM, Jupiter JB. Distal radius fractures—classification of treatment and indications for surgery. *Hand Clin.* 2010;26:37–42.
11. McQueen M, Caspers J. Colles fracture: does the anatomical result affect the final function? *J Bone Joint Surg Br.* 1988;70:649–651.
12. Gofton WT, Gordon KD, Dunning CE, et al. Soft-tissue stabilizers of the distal radioulnar joint: an in vitro kinematic study. *J Hand Surg Am.* 2004;29:423–431.
13. Ward LD, Ambrose CG, Masson MV, et al. The role of the distal radioulnar ligaments, interosseous membrane, and joint capsule in distal radioulnar joint stability. *J Hand Surg Am.* 2000;25:341–351.
14. Watanabe H, Berger RA, Berglund LJ, et al. Contribution of the interosseous membrane to distal radioulnar joint constraint. *J Hand Surg Am.* 2005;30:1164–1171.
15. Moritomo H, Noda K, Goto A, et al. Interosseous membrane of the forearm: length change of ligaments during forearm rotation. *J Hand Surg Am.* 2009;34:685–691.
16. Moritomo H. The distal oblique bundle of the distal interosseous membrane of the forearm. *J Wrist Surg.* 2013;2:93–94.
17. Graham TJ. Surgical correction of malunited fractures of the distal radius. *J Am Acad Orthop Surg.* 1997;5:270–281.
18. Turner RG, Faber KJ, Athwal GS. Complications of distal radius fractures. *Orthop Clin North Am.* 2007;38:217–228.
19. Wijffels MM, Orbay JL, Indriago I, et al. The extended flexor carpi radialis approach for partially healed malaligned fractures of the distal radius. *Injury.* 2012;43:1204–1208.
20. Jupiter JB, Rüedi T. Intraoperative distraction in the treatment of complex nonunions of the radius. *J Hand Surg Am.* 1992;17:416–422.
21. Ring D, Jupiter JB. Nonunion of the distal radius. *Tech Hand Up Extrem Surg.* 2002;6:6–9.
22. Ross M, Allen L, Couzens GB. Correction of residual radial translation of the distal fragment in distal radius fracture open reduction. *J Hand Surg Am.* 2015;40:2465–2470.
23. Hepper CT, Tsai MA, Parks BG, et al. The effect of distal radius translation in the coronal plane on forearm rotation: a cadaveric study of distal radius fractures. *J Hand Surg Am.* 2014;39:651–655.
24. Rapley JH, Kearny JP, Schrayner A, et al. Ulnar translation, a commonly overlooked, unrecognized deformity of distal radius fractures: techniques to correct the malalignment. *Tech Hand Up Extrem Surg.* 2008;12:166–169.